

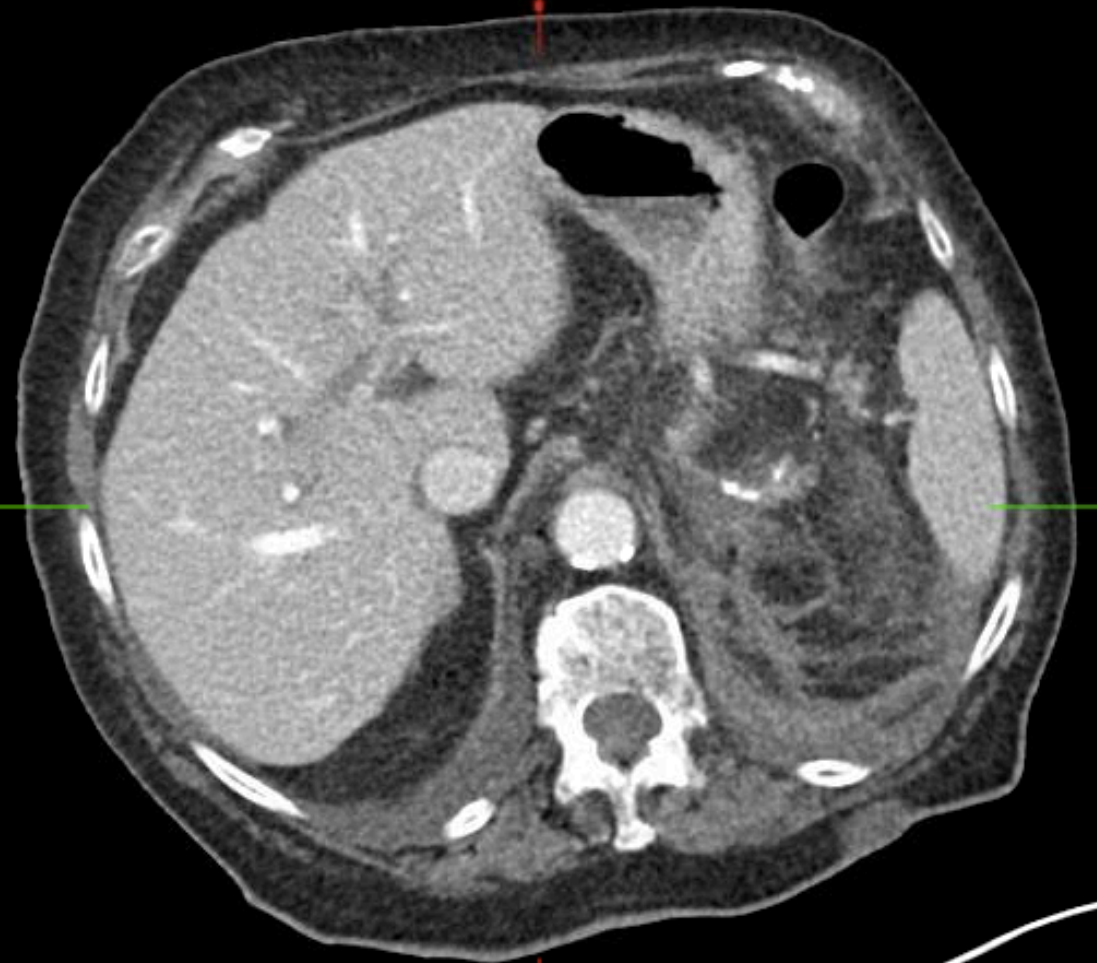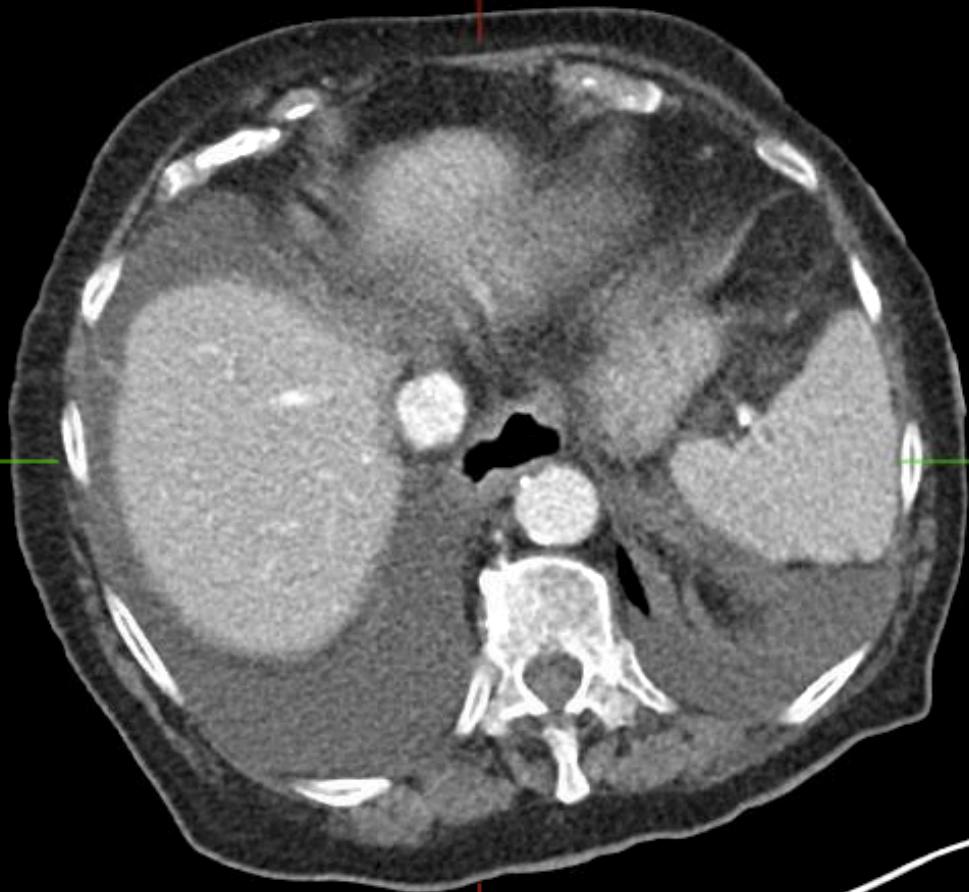
Radiology Presentation

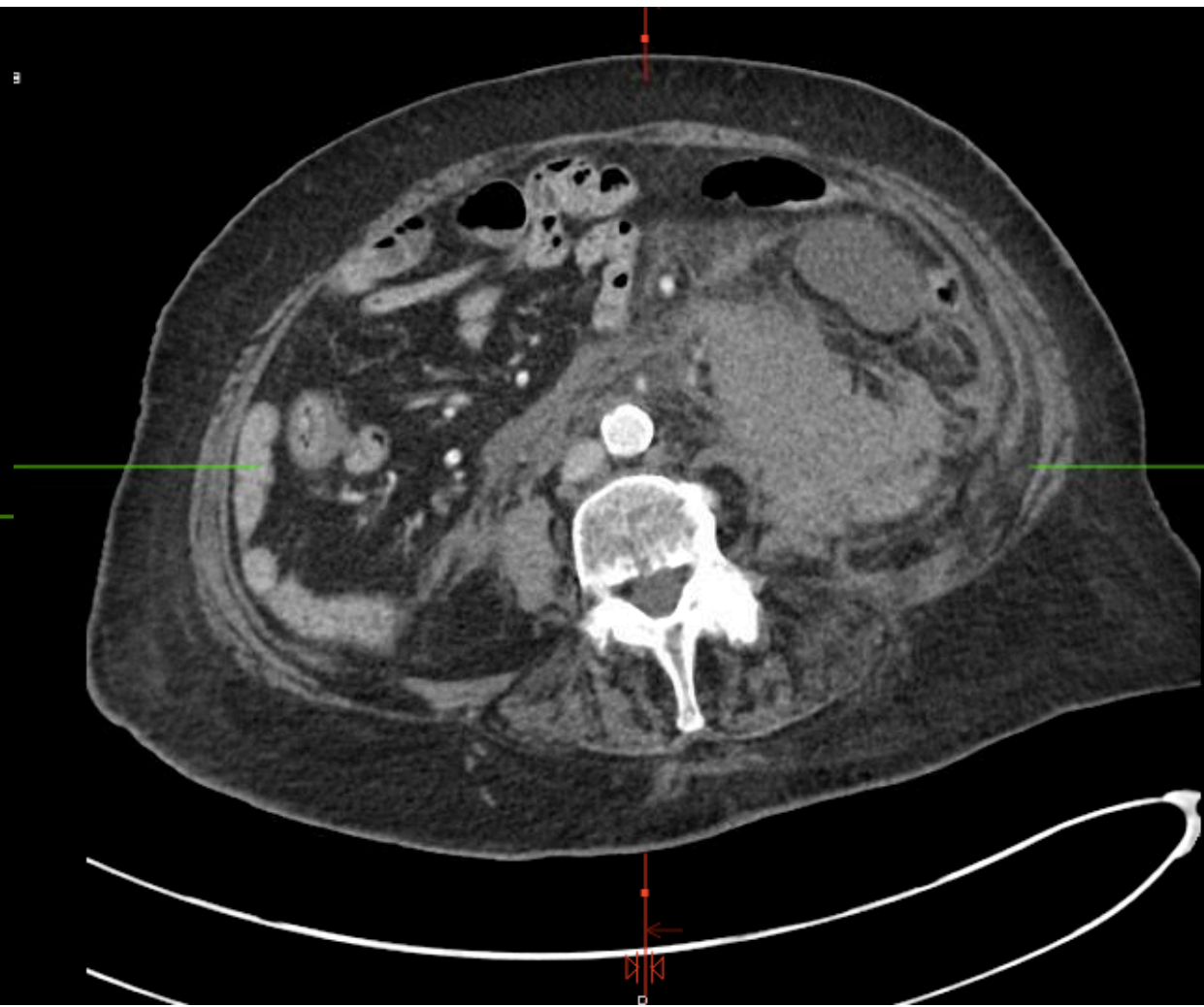
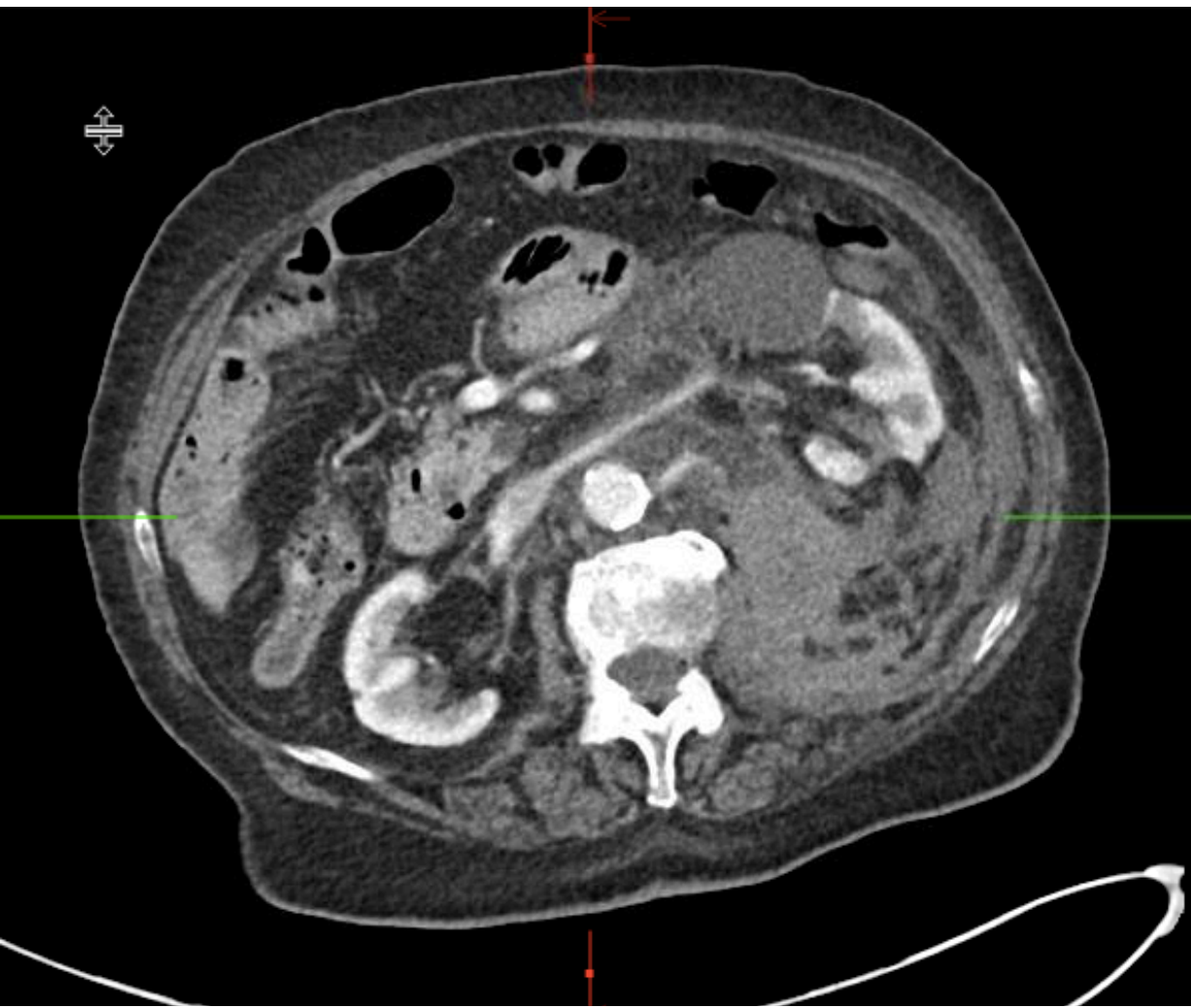Judy Deng 10/4/2018

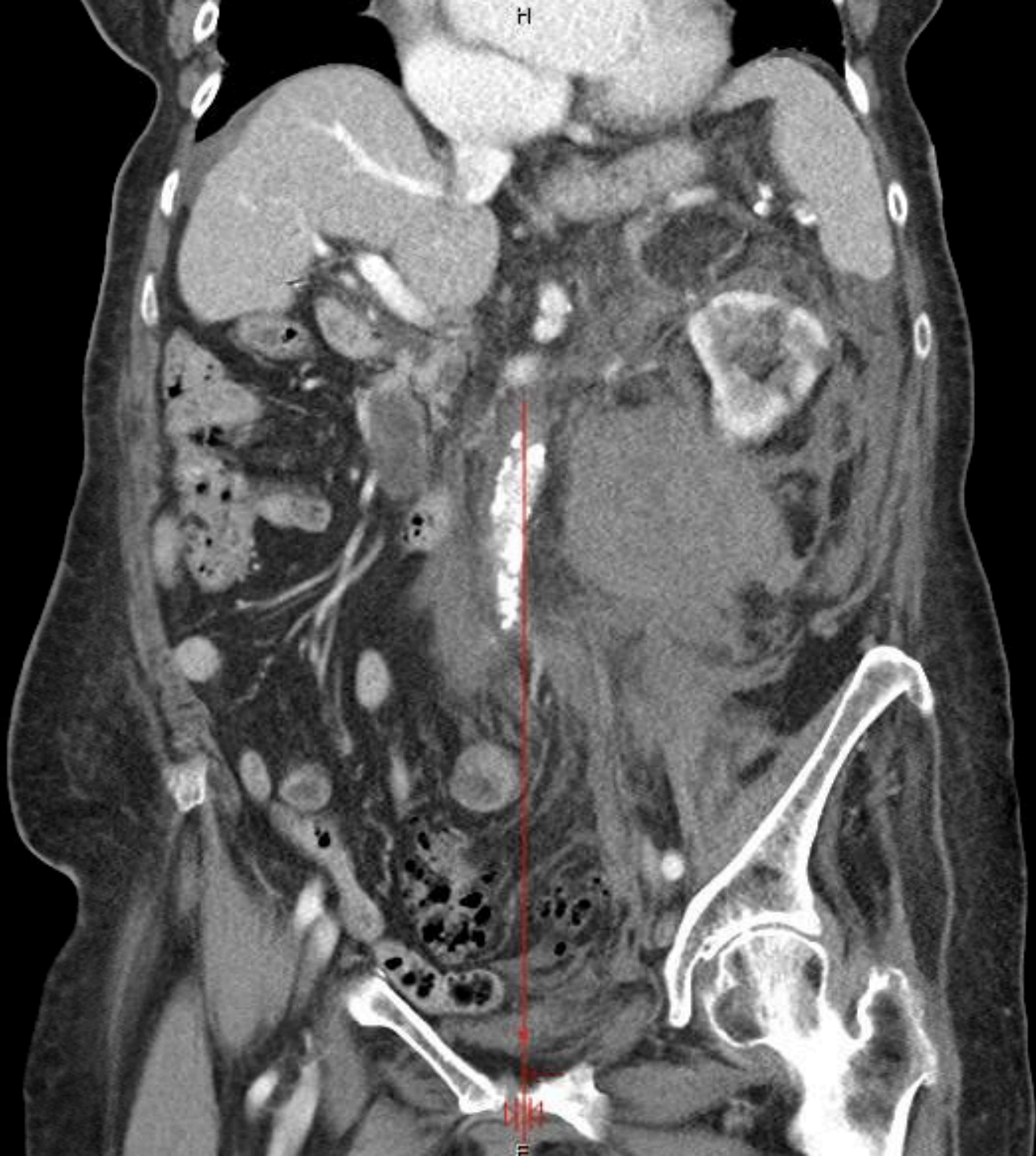94F presents to ED with generalized weakness, diarrhea and abdominal pain

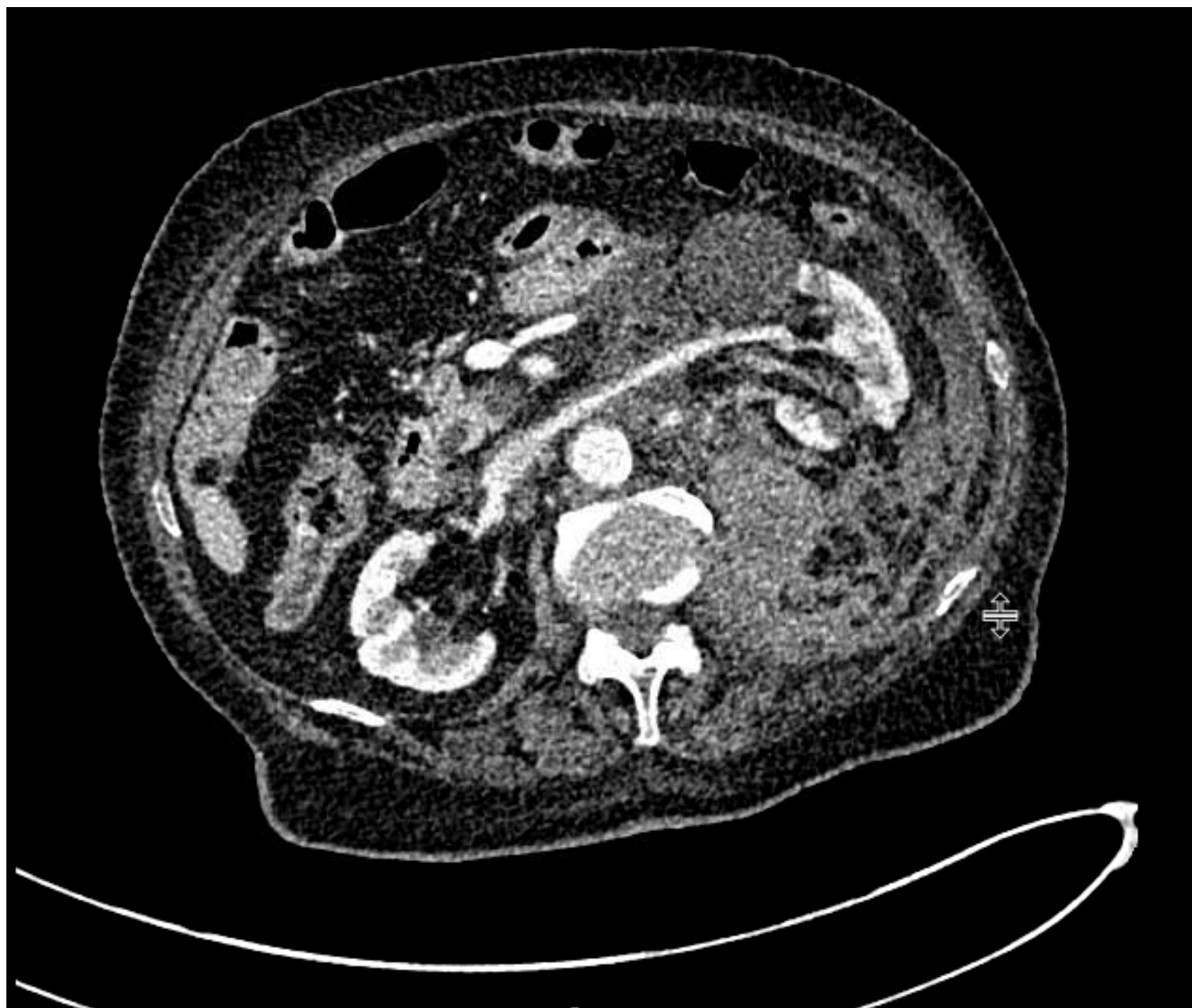- **History:** Atrial fibrillation (started on **Xarelto** 1 week prior), CHF, Pulmonary hypertension, CLL, recent admission for pulmonary edema
- **Labs:**
 - BP: **81/41**
 - Pulse: 92
 - WBC: **26** (9/19/2018) from 13.3 (9/12/2018)
 - Hgb/Hct: **10/32.2** (9/19/2018) from 12.8/39.7 (9/12/2018)
- **Physical**
 - Not in distress, pleasant
 - Mild pain on left flank

CT A/P w IV Contrast









Spontaneous retroperitoneal hemorrhage with active extravasation from the kidneys

There is a large left retroperitoneal hematoma posterior to the left kidney that appears to be extending from the inferior pole of the left kidney.

Hemorrhage is seen dissecting through the fascial layers of the left peri-renal fat. There are several large renal cysts with one 3.7 cm cystic lesion measuring attenuation greater than simple fluid, and possibly representing a mass, image 285 of series 4. On image 333 of series 4 there is some serpiginous high density material within the hematoma that is concerning for **active extravasation, this is extending from the inferior pole left kidney.** On delayed sequence, there is a larger area of higher attenuation, confirming the findings. **The bulk of the hematoma measures approximately 12 x 10 x 5 cm.** However, more hemorrhage is seen in the deep pelvis and left retroperitoneum, elevating and displacing the abdominal structures to the right.

Hospital Course

→ Admitted

→ IR:

→ Identified active contrast extravasation from a lower pole sub-segmental branch

→ embolization

→ MICU

→ Discharged 9/25/2018